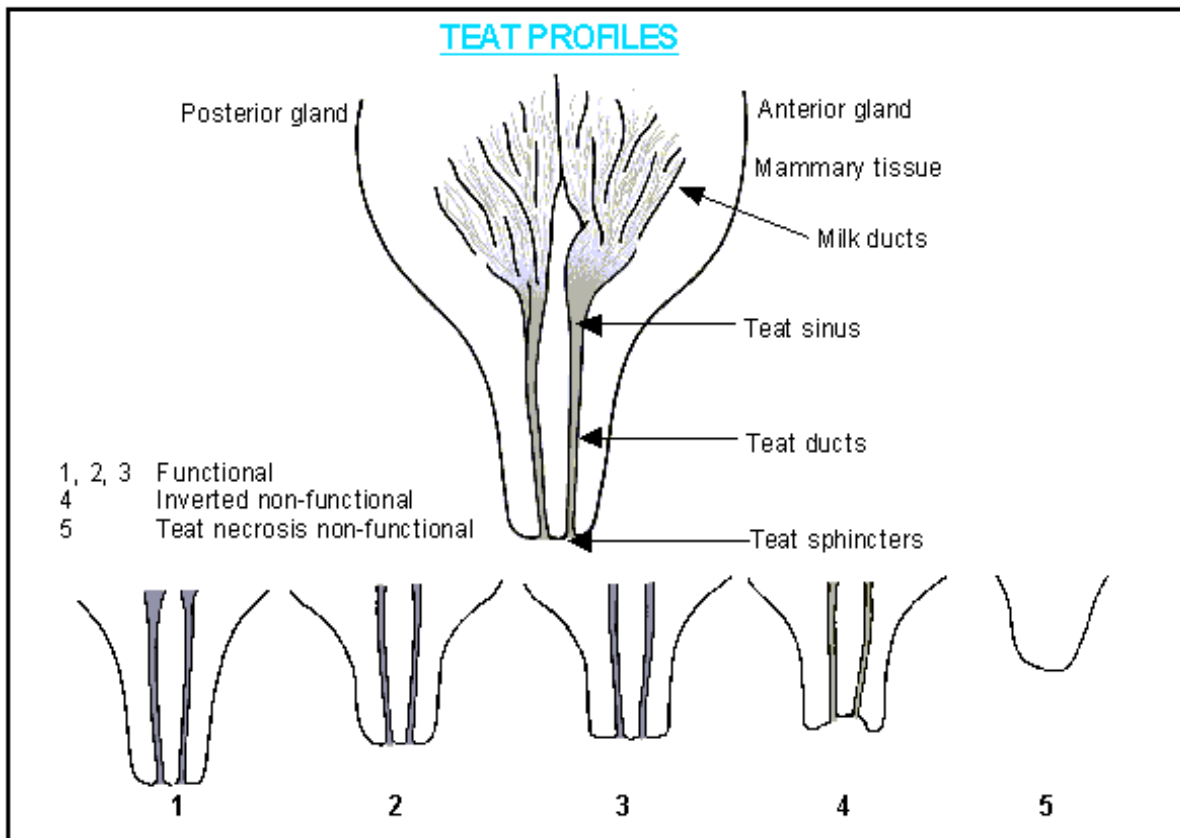


## Teat Structure and why inspection is important

Figures 1,2,3 appear to be normal and should be functional. Figure 4: If the teat sphincter cannot be seen at eye level it is likely that such a teat will remain inverted and will not be functional. This is important to appreciate when selecting or receiving a gilt for breeding. Some inverted nipples will become more normal and be functional when the mammary gland develops but when selecting you cannot take the chance. Figure 5 should never be counted as a teat.

Note that each teat has two orifices and teat ducts which drain two quite separate mammary glands, front (anterior) and back (posterior).



(Fig.1-7)

Most hog associations including the RWHA require a minimum of twelve (12) evenly spaced teats in both boars and gilts that appear they would function normally when needed. Teats are inherited so boars must be included even though they do not produce milk or nurse young. The number is selected to allow the sow to nurse all or most litters without competition. Evenly spaced is used to allow room for the proper functioning of the teat. Now imagine this teat full of milk. Evenly spaced is for this reason. There's much more going on in the teat than is visible to the eye.

This guide also helps to show nipple or teat forms. Becoming familiar with them when selecting your breeding stock will help you in the future. #5, Teat necrosis or non-functional is usually called a blind teat. They can be placed anywhere along the teat line but are found more often as the last in line near the inner thighs. They should never be counted as functional teats. They will not ever produce nourishment (milk for their young).

Teat injury is fairly common and can cause the teat to become non-functioning. It's not a reason to remove the hog from registration or to cull for freezer camp, but does show another reason why an initial minimum of 12 is wise and necessary.